

Therapist Management of Distal Radius Fracture

October 18, 2019

Cindy Quinnelly, MS, OTR/L, CHT

- DRF is the most common fracture in human skeleton ,comprising 18% of all fractures and affecting an estimated 85,000 Medicare beneficiaries each year.
 - (Court-Brown M, 2006);(Chung et al JBJS 2009)

Outline

- Clinical Evaluation: First visit- establish treatment plan of care. Patient education regarding the orthopedic procedure and anticipated time frames for therapy program
- Understanding the therapeutic approach for Outpatient management of distal radius fractures.
- Special considerations in distal radius fracture management.

That First Visit

- The referral - “Distal radius fracture- evaluate and treat”
 - Call or look up the operative note
 - Look at precautions or comments on the referral
 - Look up the x-rays

The First Visit

- The patient
 - Anxious, often in pain, fearful about loss of independence often poorly educated regarding the injury and come expecting for therapy to be painful.
 - Understand the co-morbidities - home situation- support system- encourage the family to participate in the therapy sessions.
 - Assuring the patient - power to touch/the value of humor /the art of therapy.

What are you treating?

- Minimally displaced fracture, or non-displaced extra articular fracture.
- Inter-articular fracture fragments.
- ORIF with volar fixed angle plates with or without locking mechanisms.
- ORIF with low profile dorsal plate(fragment -specific or inter medullary nailing): as with volar plating.

Minimally displaced fracture, or non displaced extra articular fracture

- The patient presents with orthosis/cast ...first visit may be 4-6 weeks post injury-presenting with a stiff hand, loss of tendon excursion, intrinsic tightness, shoulder impingement; home program maybe sufficient (with weekly progression of one time weekly visits) with uncomplicated DRF.

Inter-Articular Fracture Fragments

- External fixation: with or without pinning; percutaneous pinning.... First visit often as early as 24 hours PO for wound care, additional support orthosis, wrist control, Munster or posterior elbow/wrist orthosis, early motion shoulder, forearm and digits.

ORIF with Volar fixed angle plates with or without locking mechanism

- First visit 24 hours PO to 2 weeks, PO for wound care, support orthosis, short arc motion of the wrist. Monitor status of FPL, EPL/FCR.

ORIF with low profile dorsal plate (fragment
- specific or inter medullary nailing) :as with
volar plating

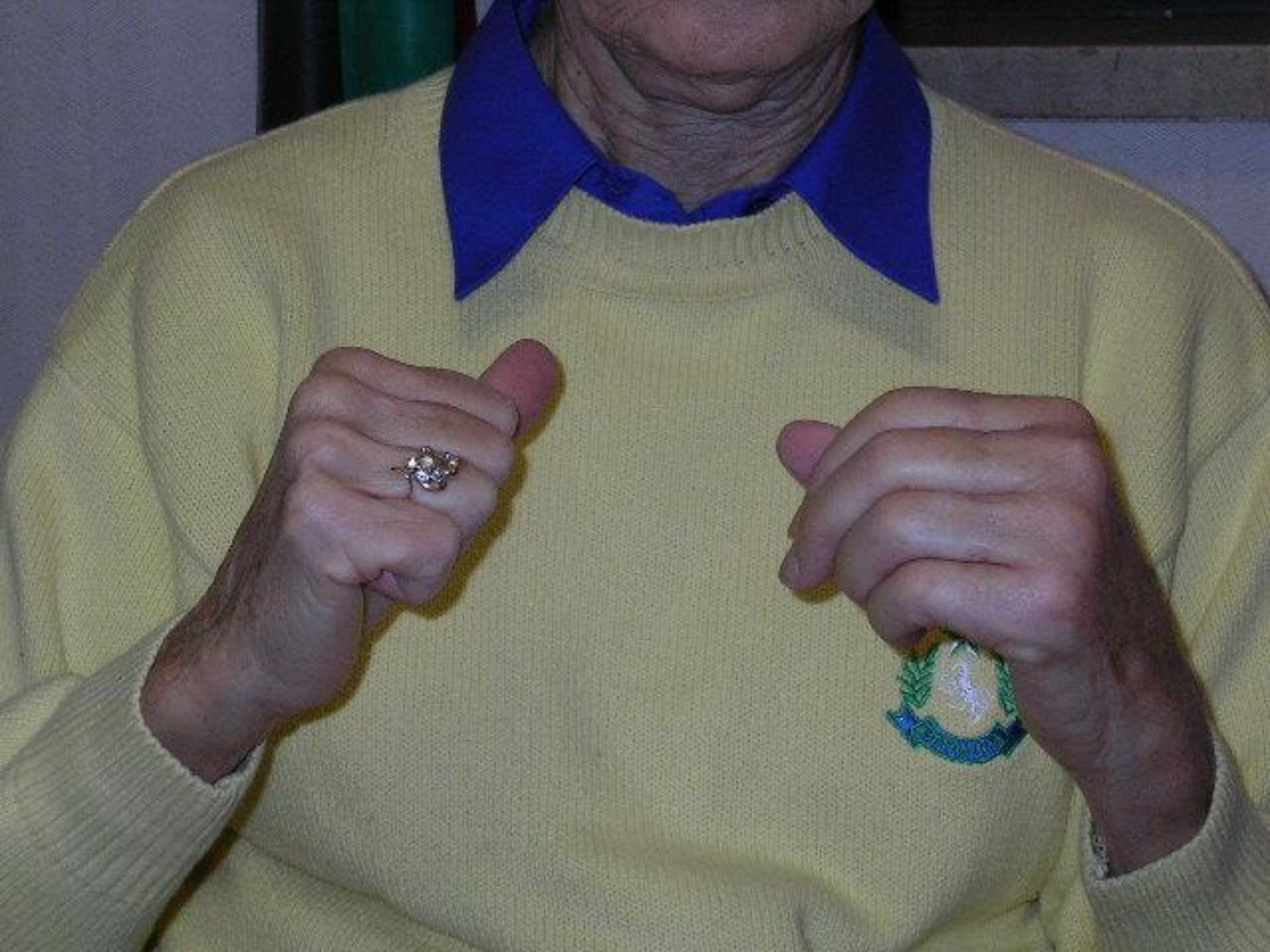- Regain digital motion/tendon glide and focus on scar management.

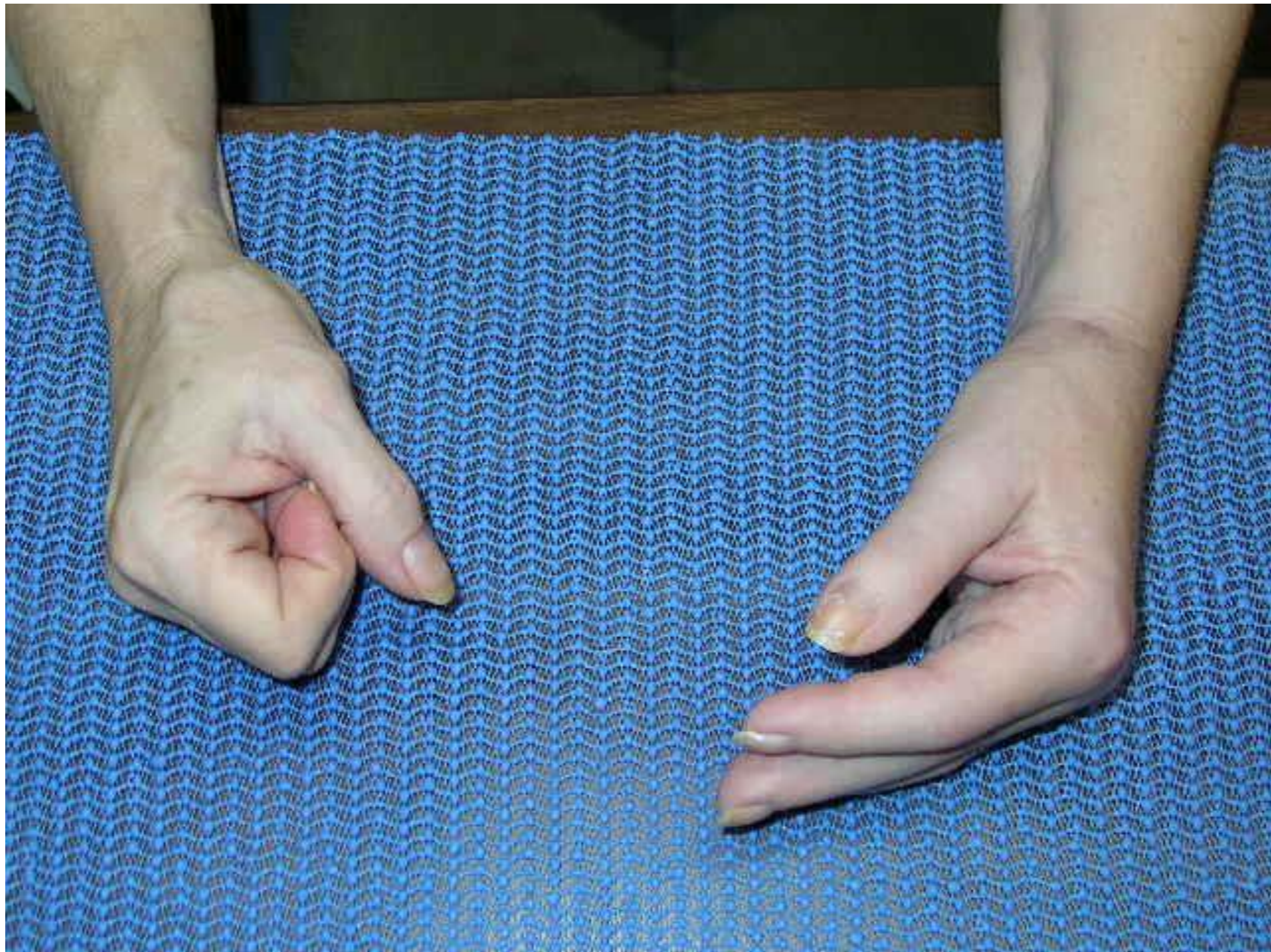
Clinical Evaluation / early intervention establish a treatment plan of care

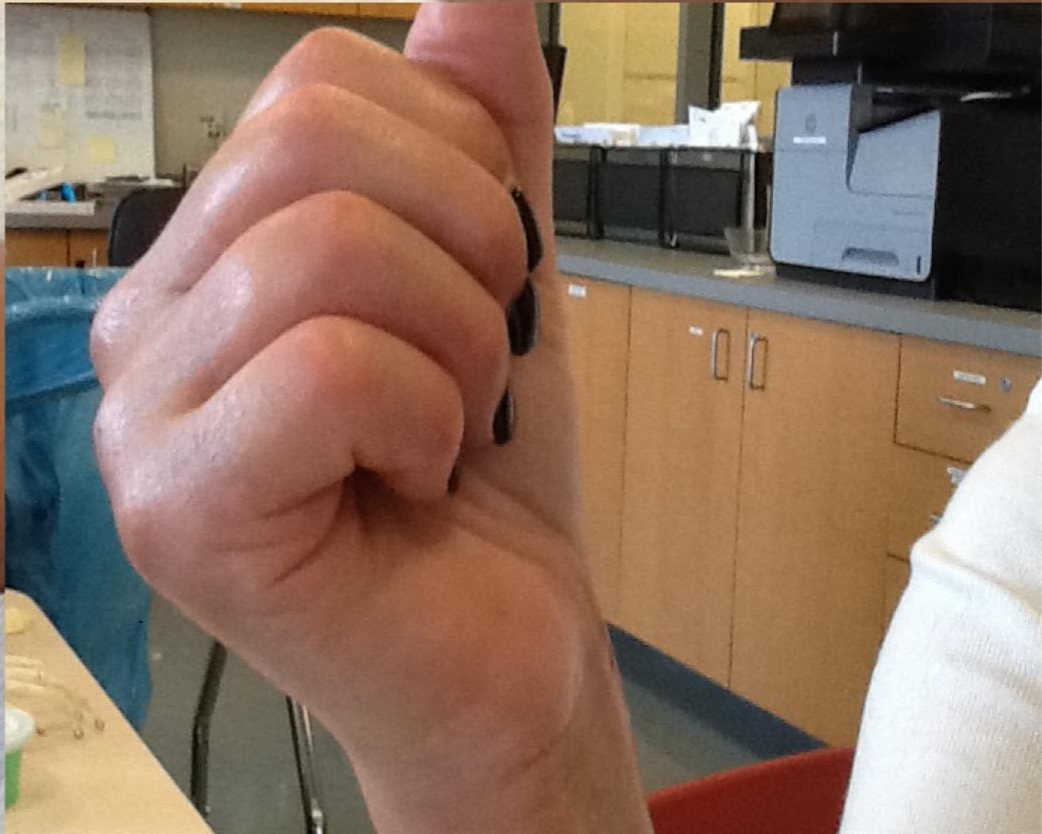
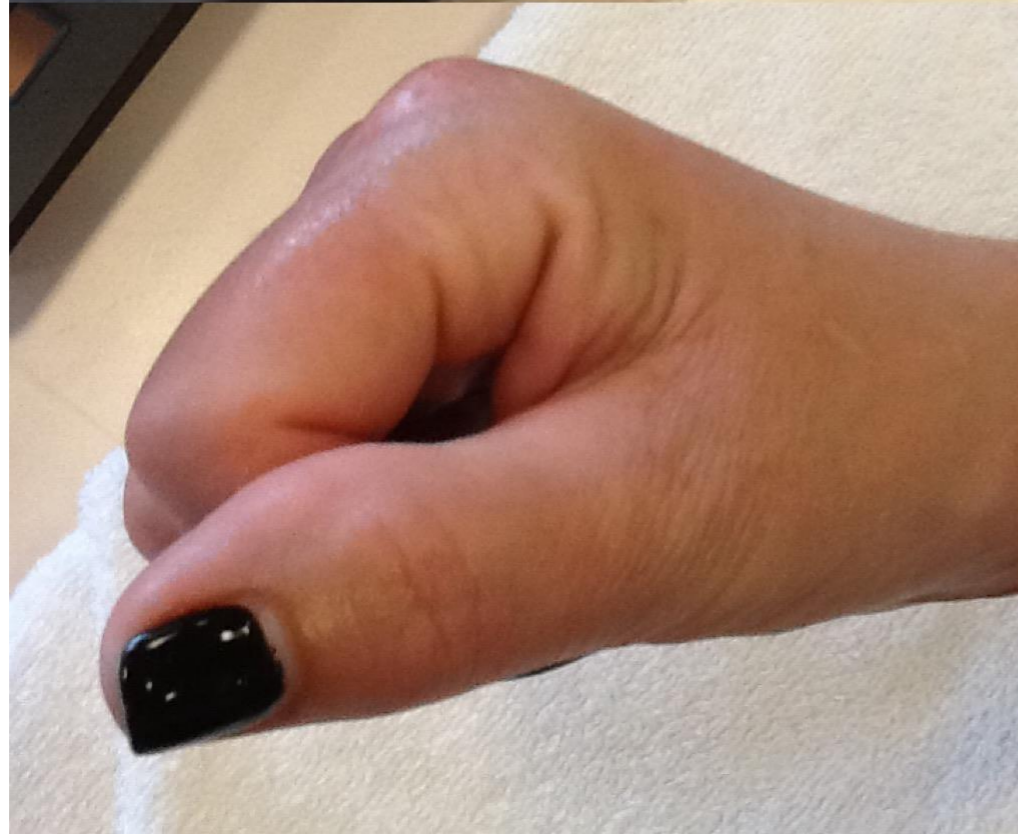
- First visit should be about pain, edema ,wound care, proper orthosis fabrication, controlled motion, education, HEP exercise and postures. Patients with wound, pins, external fixation best treatment in supine to avoid vasovagal episode.

Clinical Evaluation

- History
- Wound inspections
- Observation
- Edema
- Inflammation
- Pain, sympathetic symptoms
- Nerve
- ROM
- Custom Orthosis
- Use of a Sling
- Patient rated self report measures





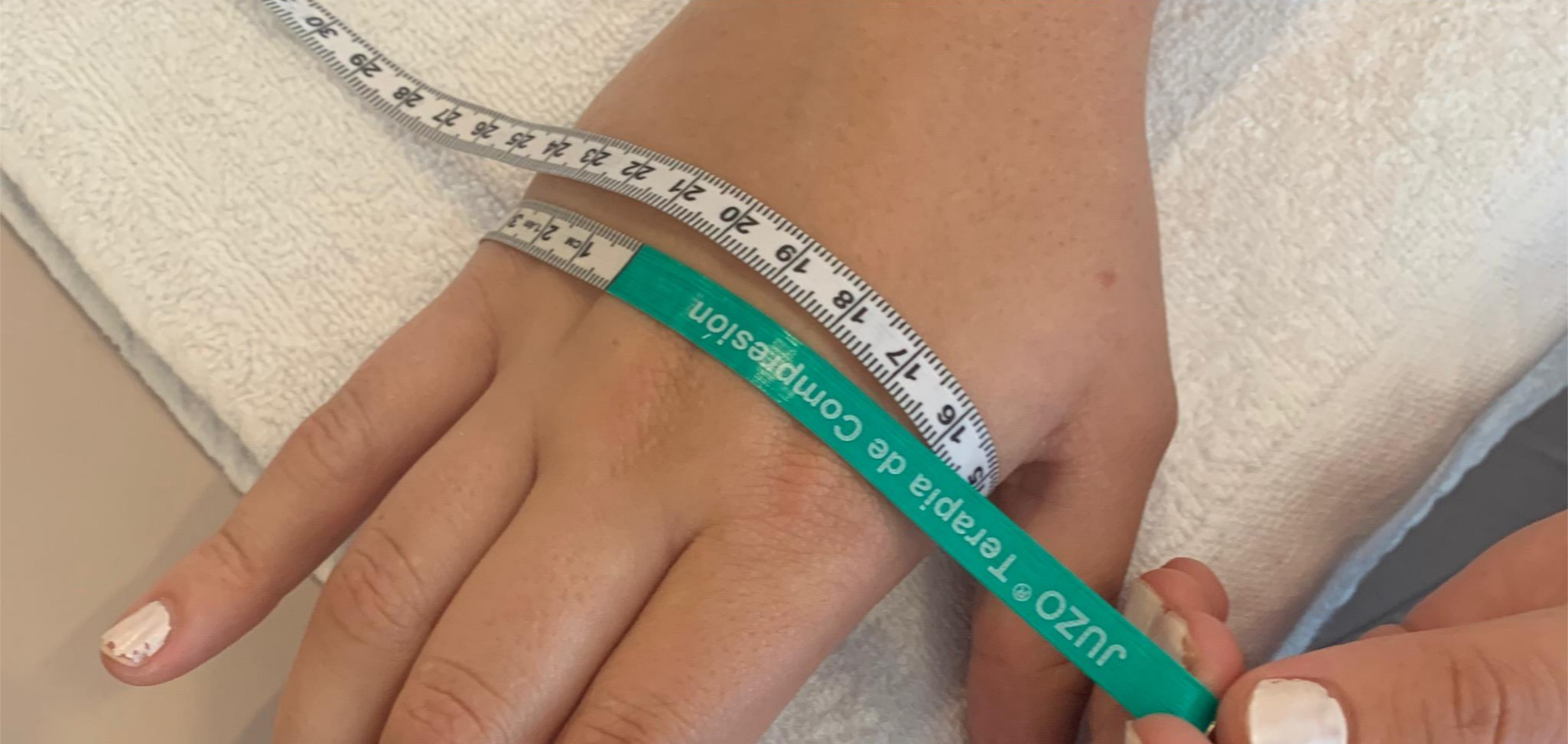
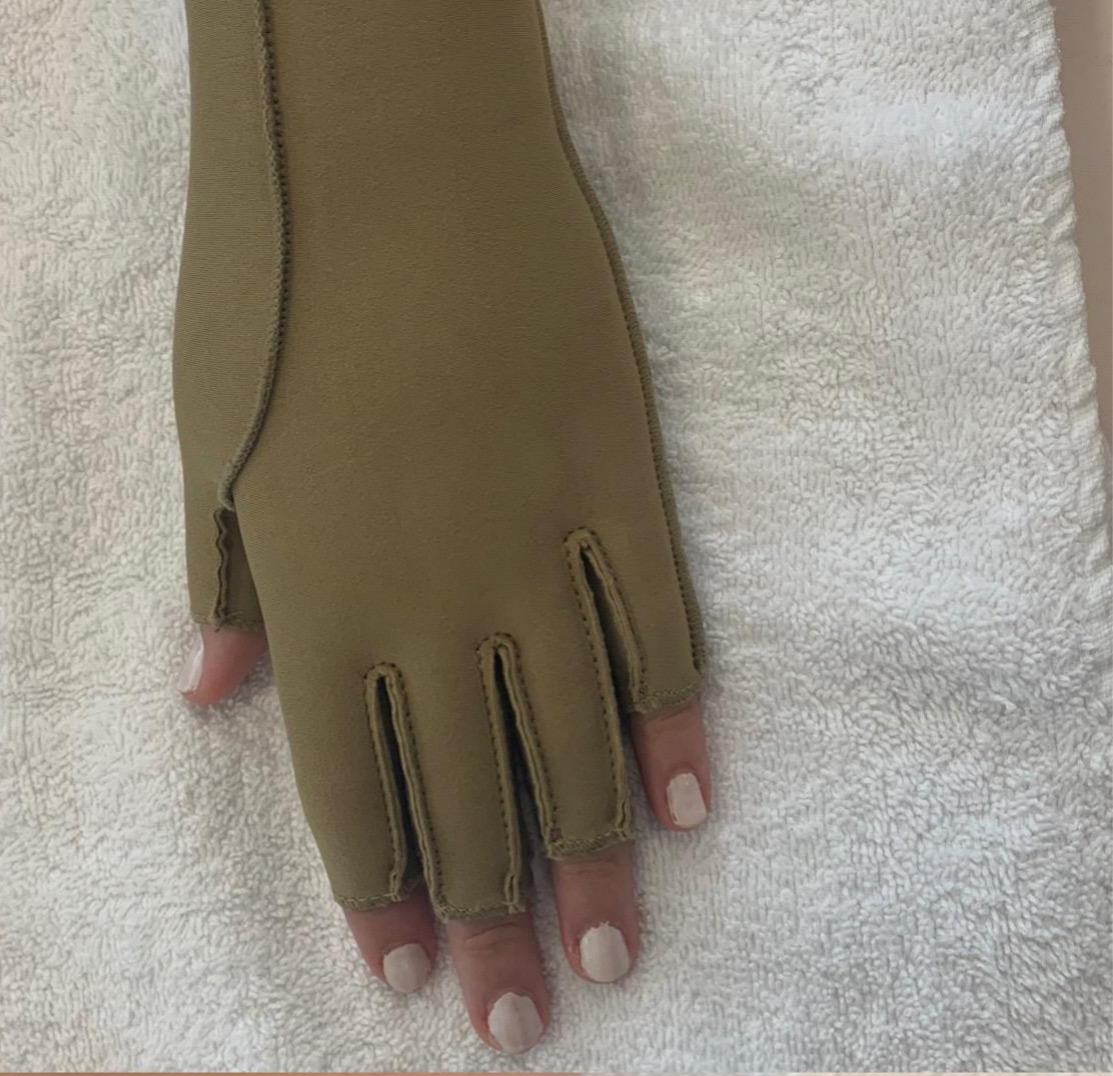
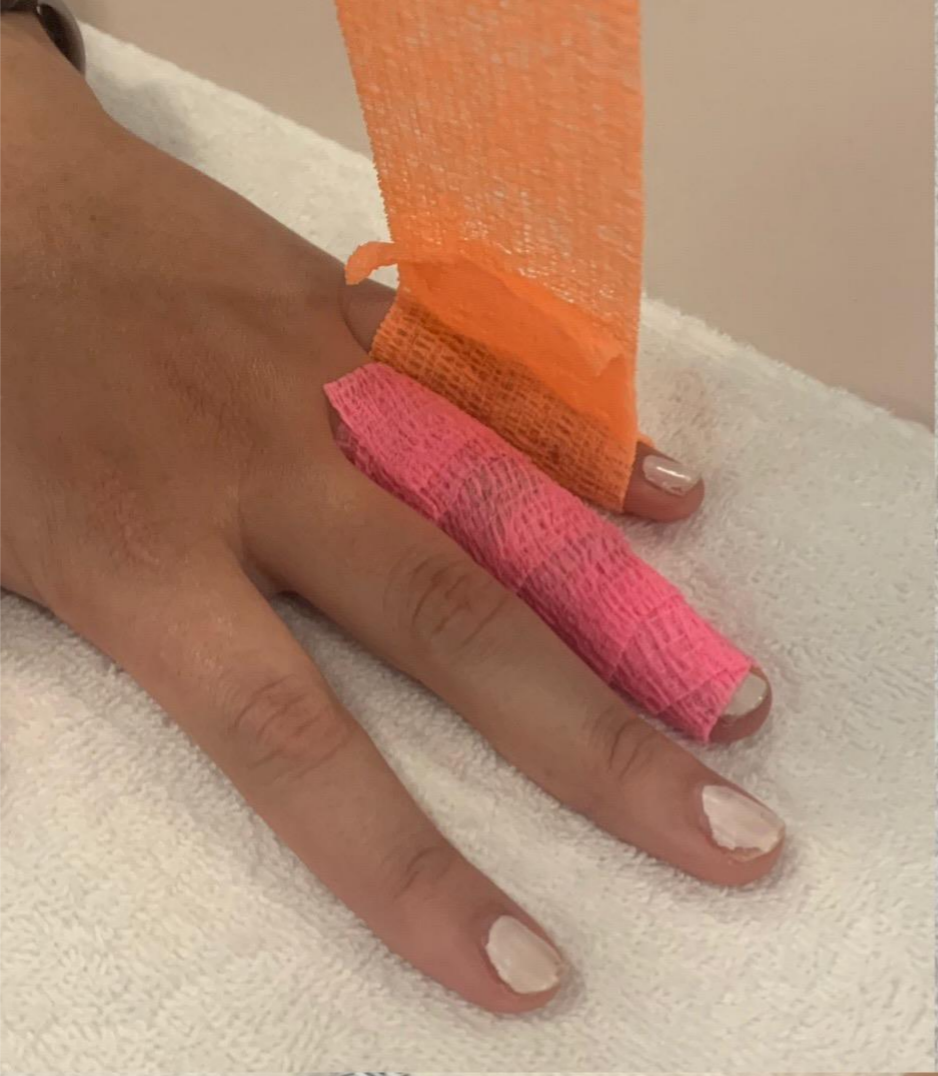Early Treatment Interventions

- Wound care - Skin and wound care for suture line- pin tracks (a conduit for infections)
- Written and family instructions
- Goal is to prevent infection and to intervene quickly if purulent drainage or sign of infection noted to MD.

Edema

- Measure girth comparisons wrist < DPC, digits.
- Manage with Manual Edema mobilization, MEM exercises
- Edema control instruction, elevation , cold compression
- Compression gloves - Coban wraps as appropriate



Inflammation

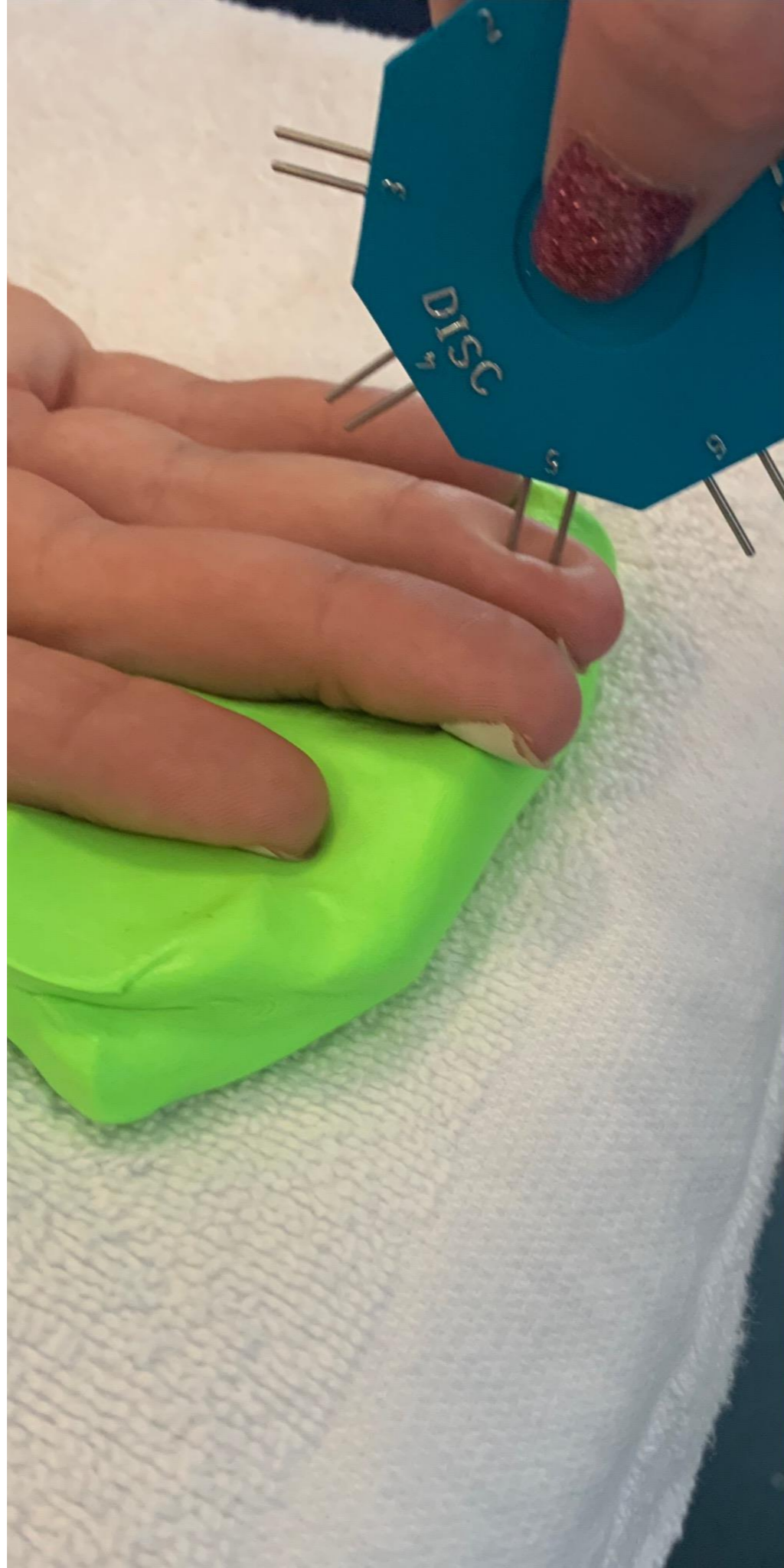
- Assess inflammatory issues in the synovial regions visually and with light stress to the tendons - (1st dorsal compartment/ the CT and at the A-1 pulley)
- Unload the tendons as appropriate with additions to orthotics or a lumbrical block support.

Pain, sympathetic symptoms

- Using the Visual Analogue Scale (VAS) to establish the severity and source of pain- tight PO dressing, improperly fitting cast or splint, wound issues/impending infection, symptoms of CT compression, DRSN symptoms, patient perceived pain with anxiety and low pain threshold.
- Treat with alterations in orthosis, edema control, alert the MD with suspected early CRPS.

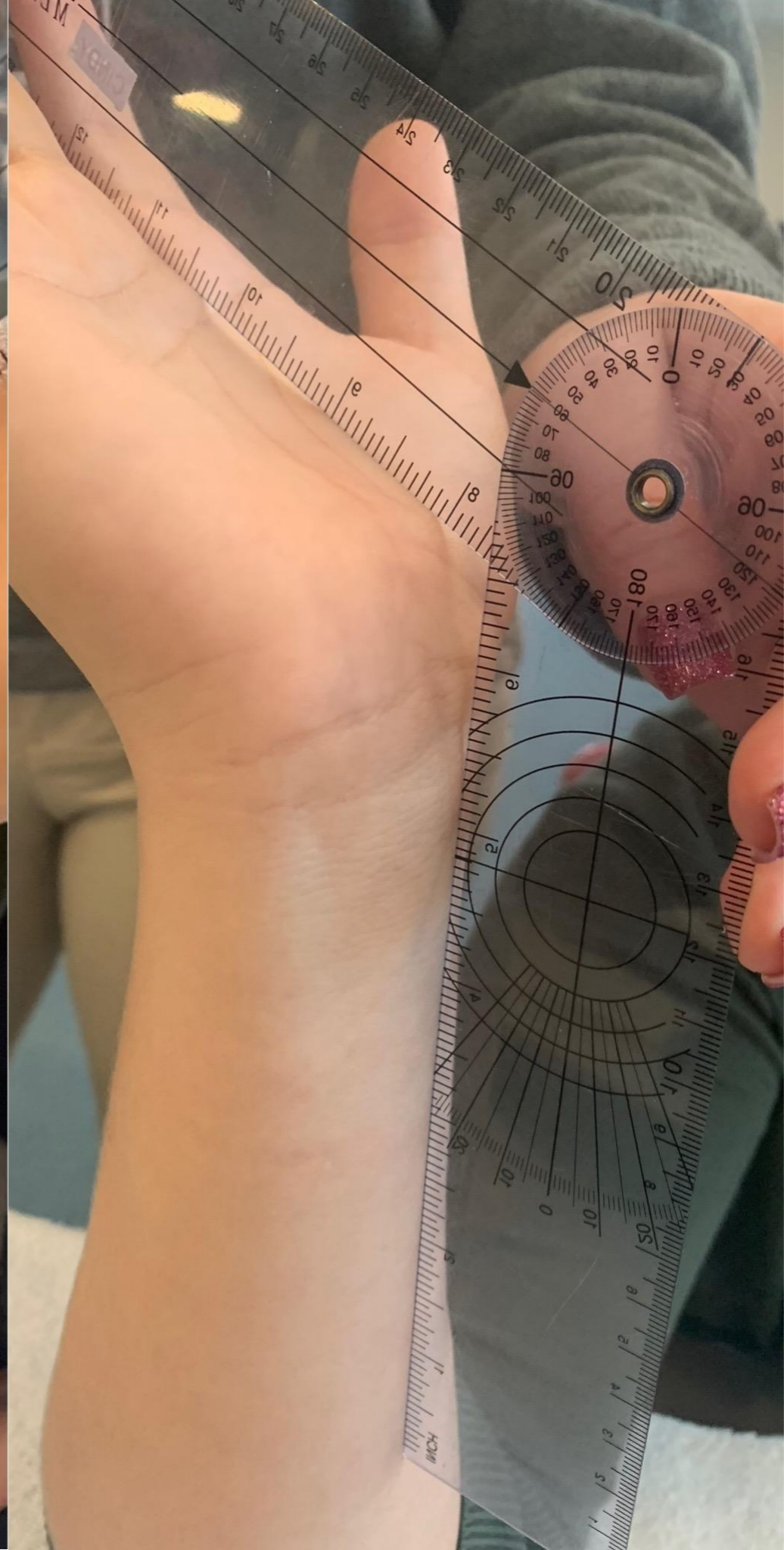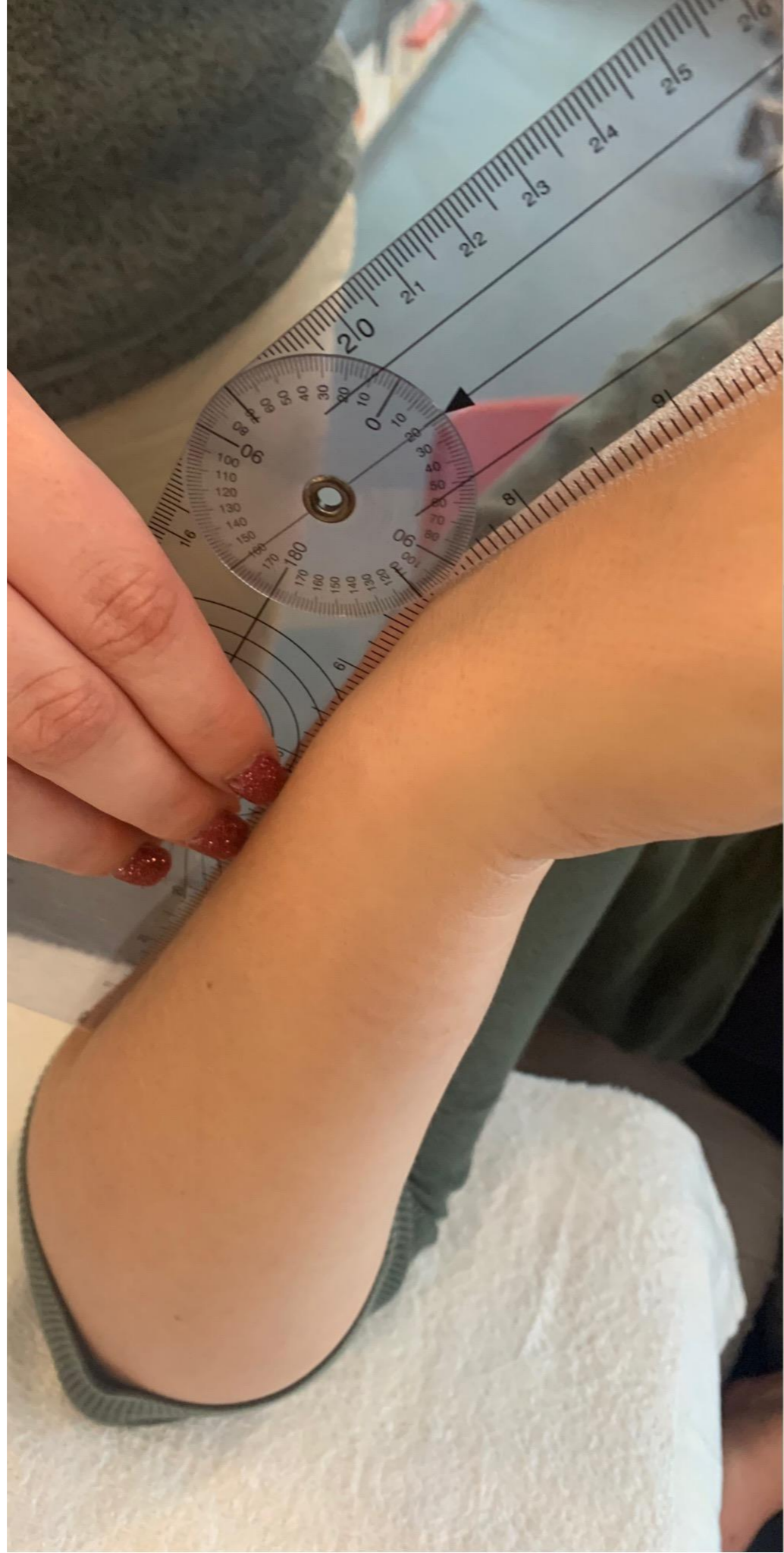Nerve

- Semmes Weinstein testing for sensibility, notes complaints of paraesthesia, burning pain, note intrinsic and extrinsic motor function.
- Consider use of TENS, interferential electrical stimulation
- Consider use of desensitization for hypersensitivity.



Range of Motion

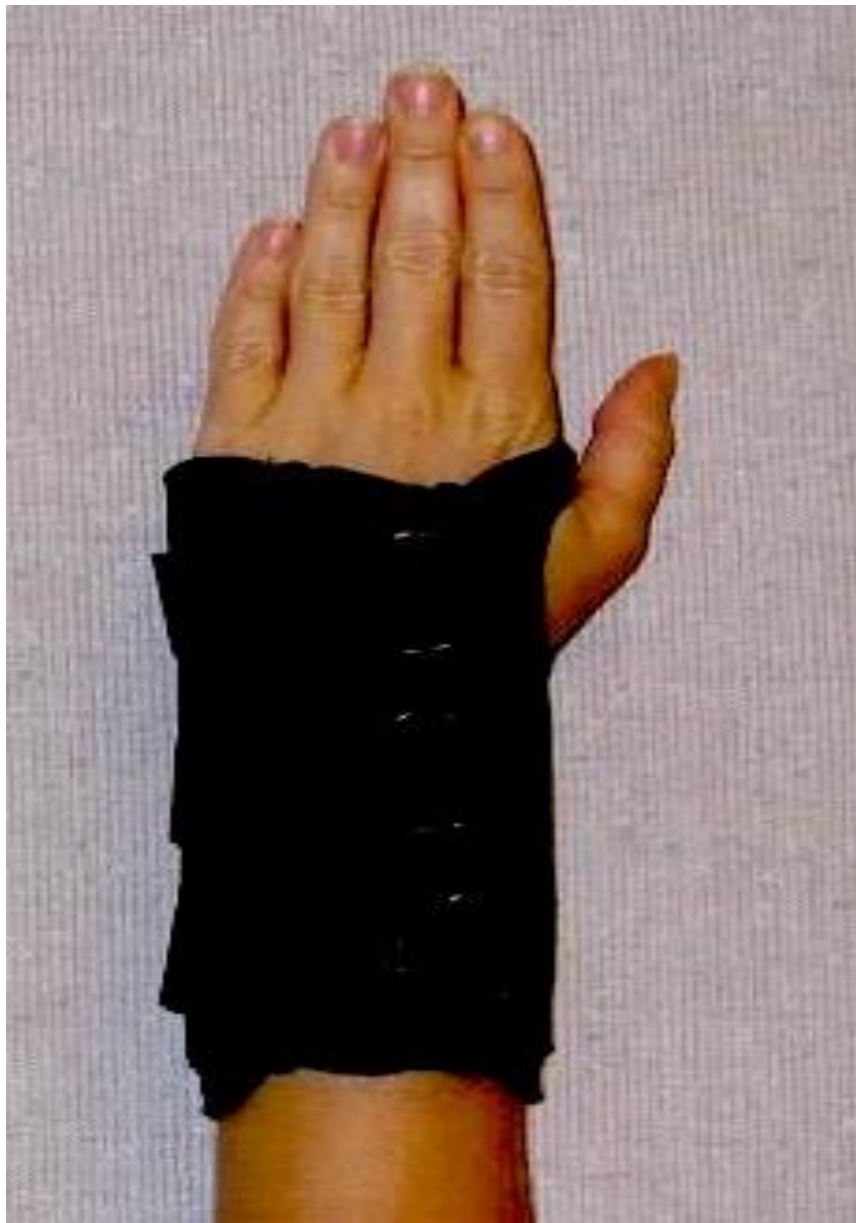- PROM, assessing joint and capsular status , AROM assessing tendon function.
- Begin early motion whenever possible with the shoulder, elbow and uninvolved digits and thumb.
- Basal thumb pain may often be a pre-existing CMC joint dysfunction with the older patients.
- With some patients a quick screen for shoulder dysfunction may prevent/address with scapular exercises by the next visit.



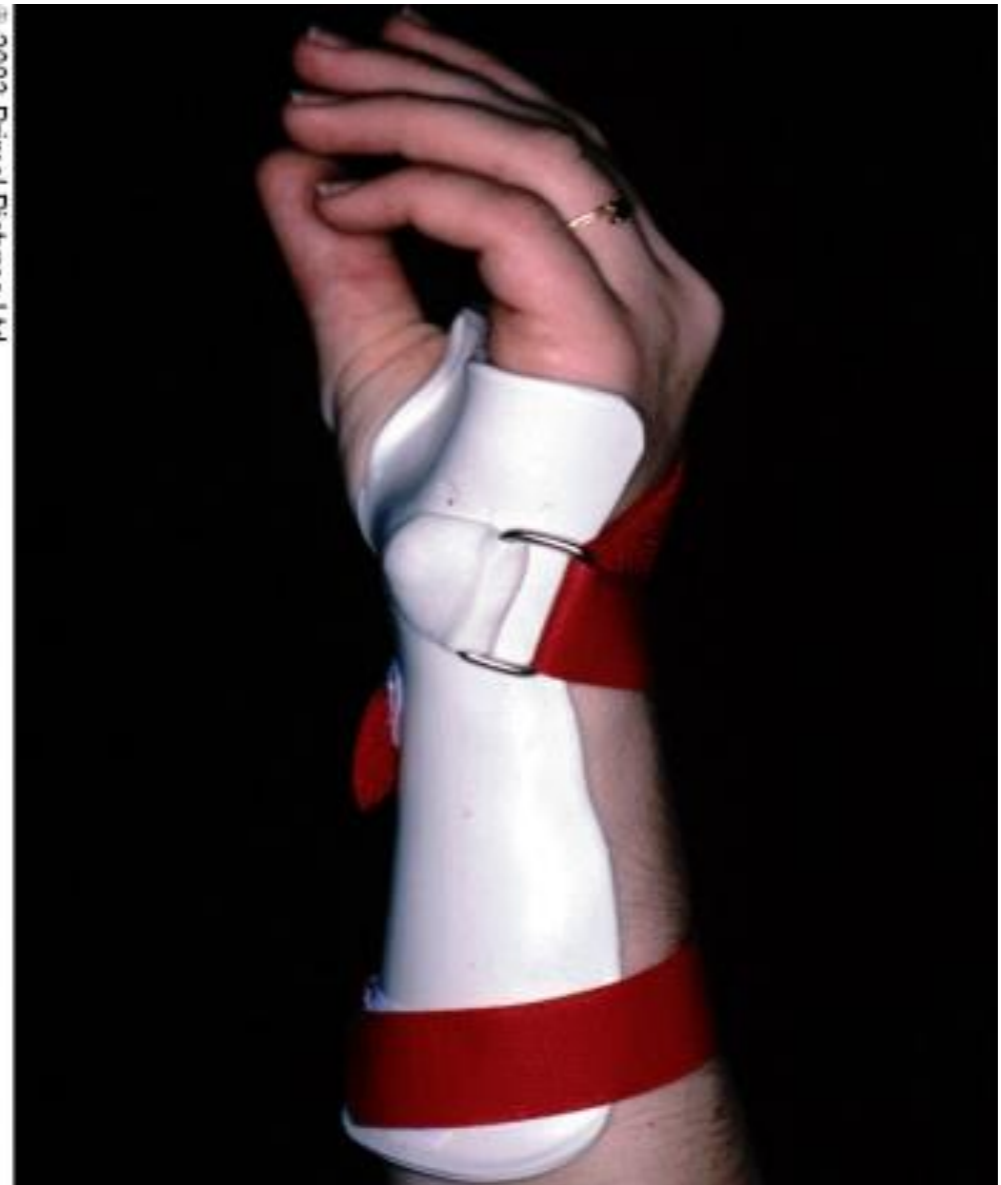Custom orthotics

- Address the need the for custom orthotics, often the patient presents in the initial visit with a prefabricated wrist support. At times there may be need for additional stabilization and pain issues related to forearm rotation, basal thumb pain and tendon inflammation.

Orthosis provide proximal stability for improved finger mobility



© 2003 Primal Pictures Ltd.



Use of a sling

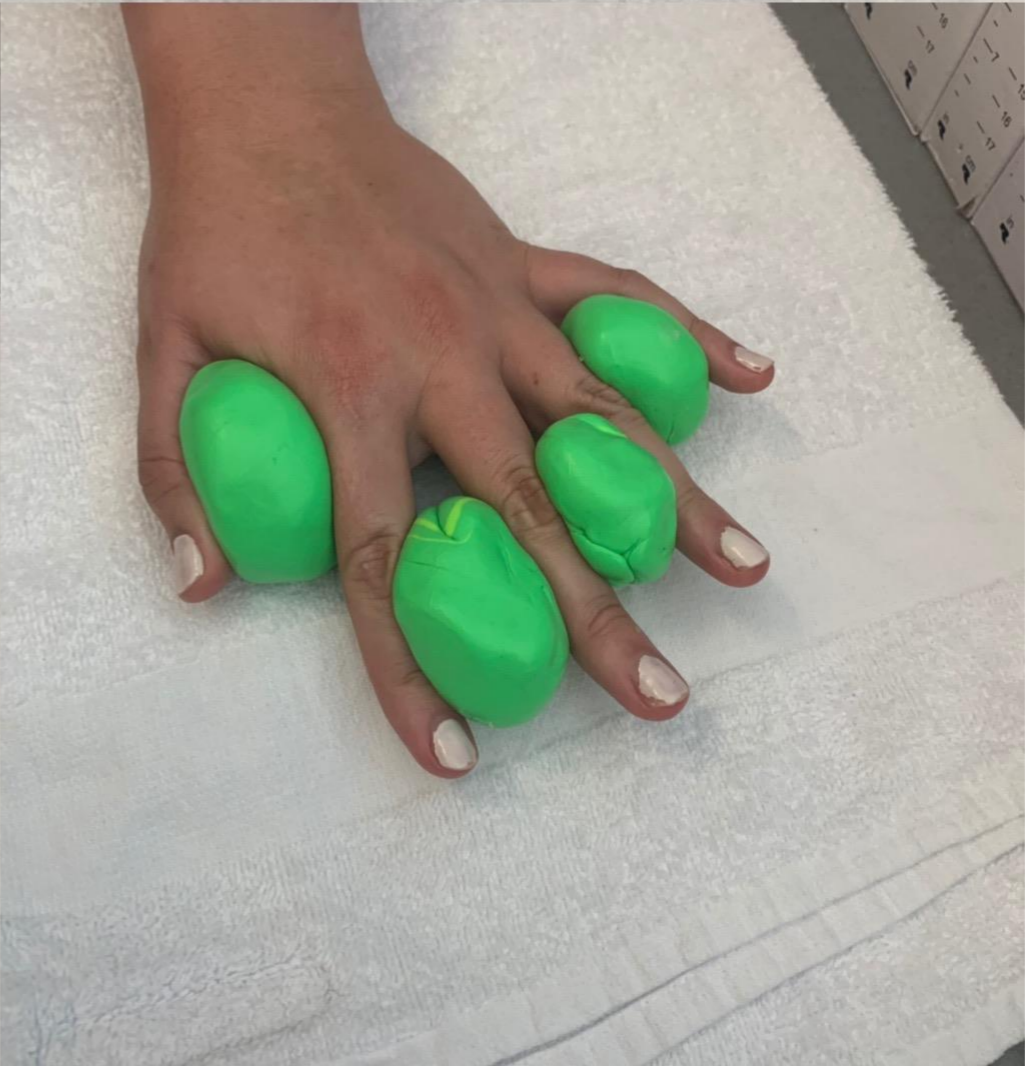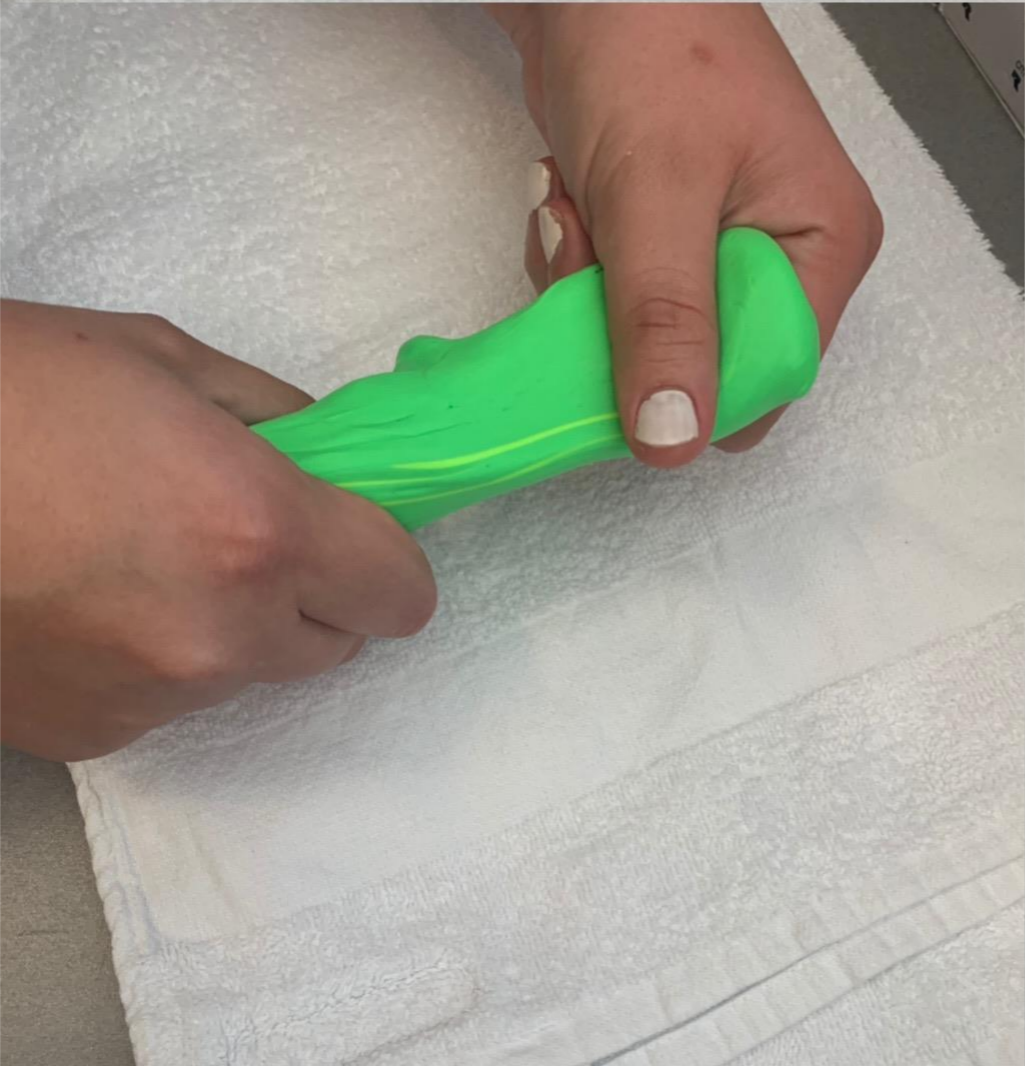- Minimize use - often used for public outings. Slings in general encourage patients protected posture of shoulder adduction and internal rotation, the hyper flexion of the elbow can increase tension on the ulnar nerve at the cubital tunnel.


Home Exercise Program

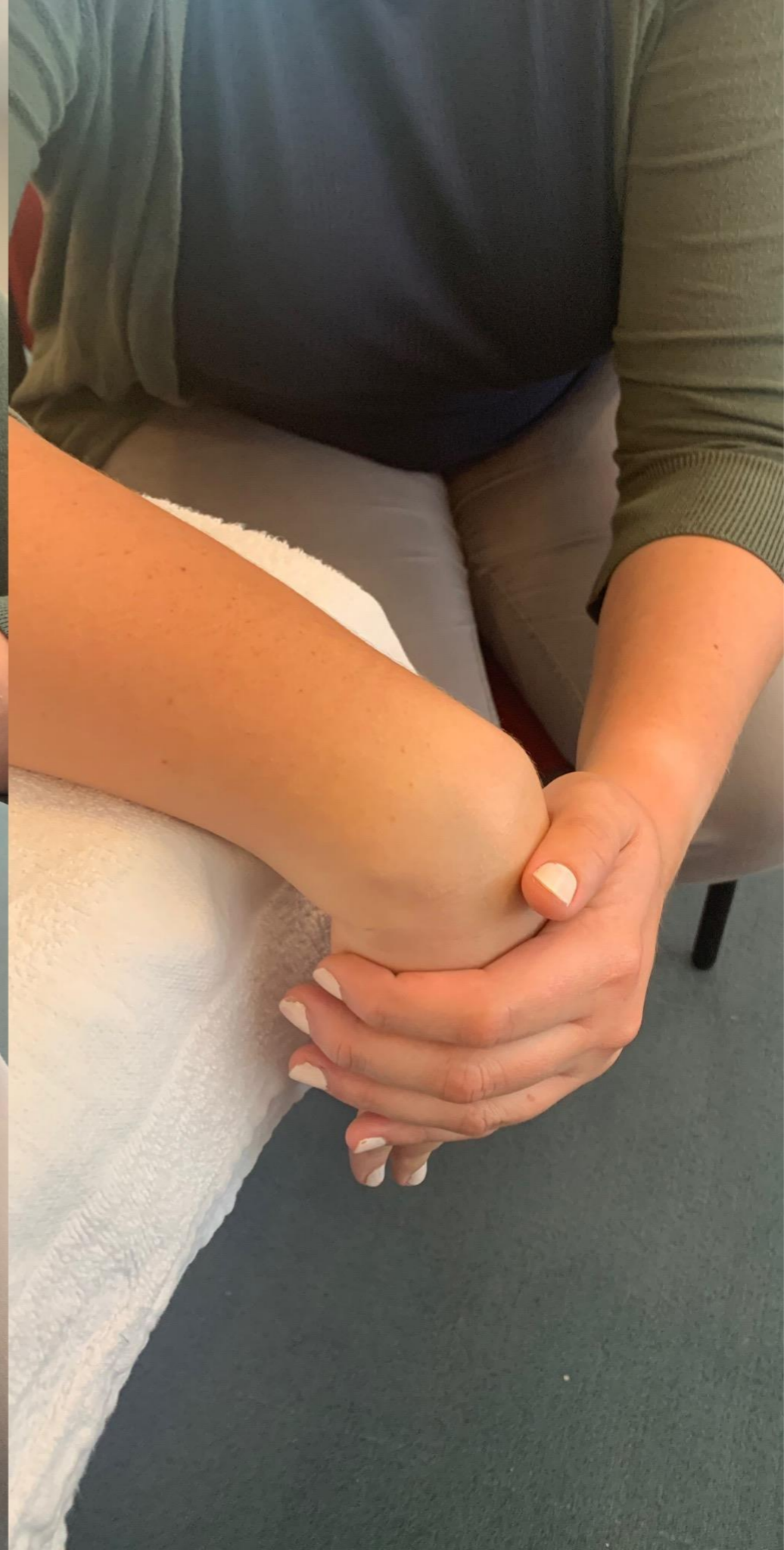- Very important part of patient education-take the time-verbal and written instructions- keep it simple and structured.
- First visit- focus on edema control, precautions, sleeping postures - controlled exercise and wound care.
- To be successful, I must empower the patient-(with my coaching), they must learn to be their own therapist

Exercise tips

- Strengthening the wrist extensors with EDC excluded to overcome maladaptive patterns of use
- Strengthening the extrinsic flexors with isometric grip using 2-3 inch dowel to prevent lumbarical excursion into the carpal canal - prevent median nerve compression and synovitis of the flexor tendons.
- Be aware of patients that have pre-existing CMC arthritis and avoid excessive thumb strengthening.
- Scapular balancing exercise with early treatment can prevent shoulder impingement issues.
- Loss of joint extensibility or tendon adhesions can be address with static progressive or dynamic orthosis which can apply low load progressive stretch to supplement HEP.

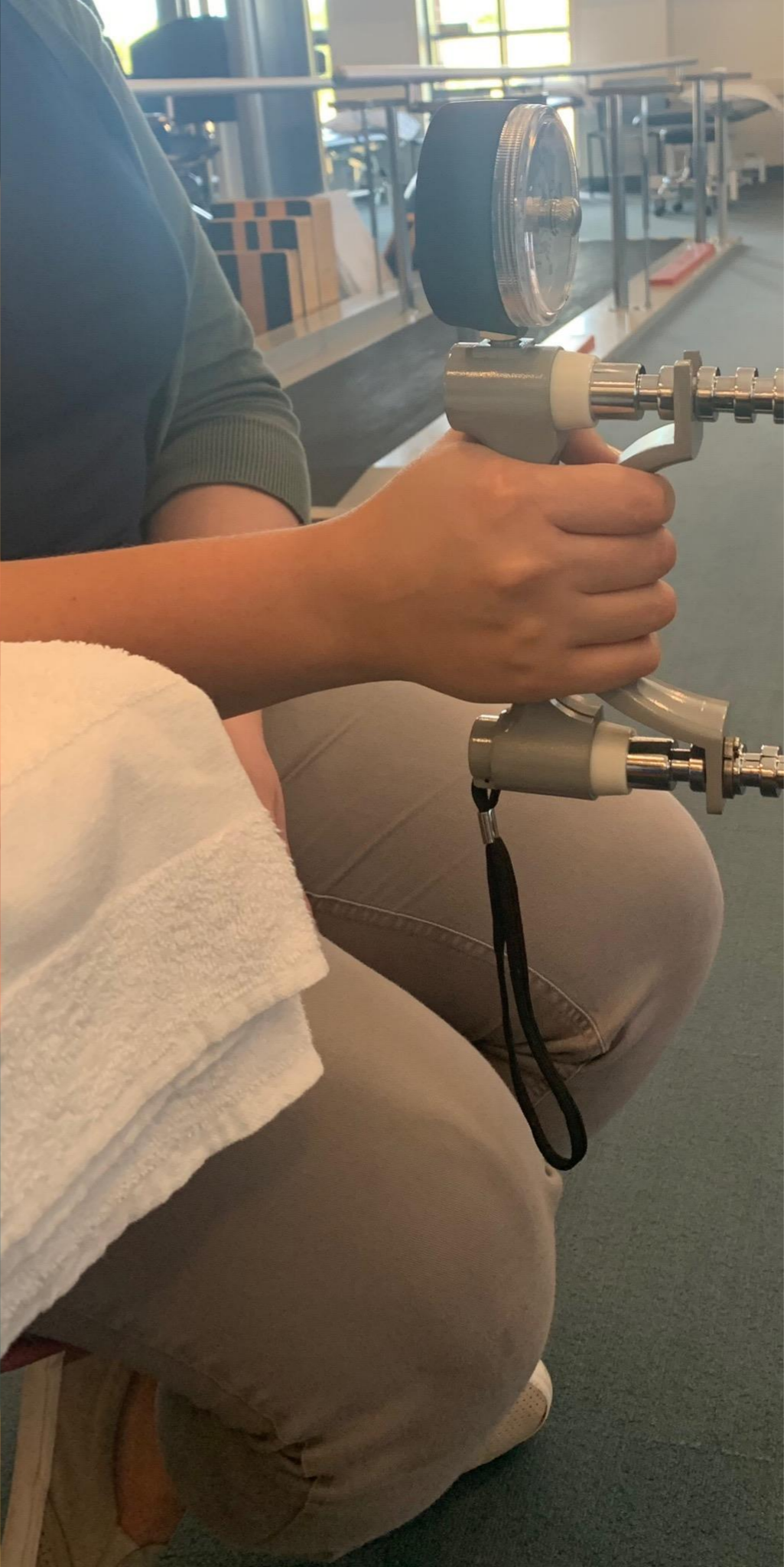




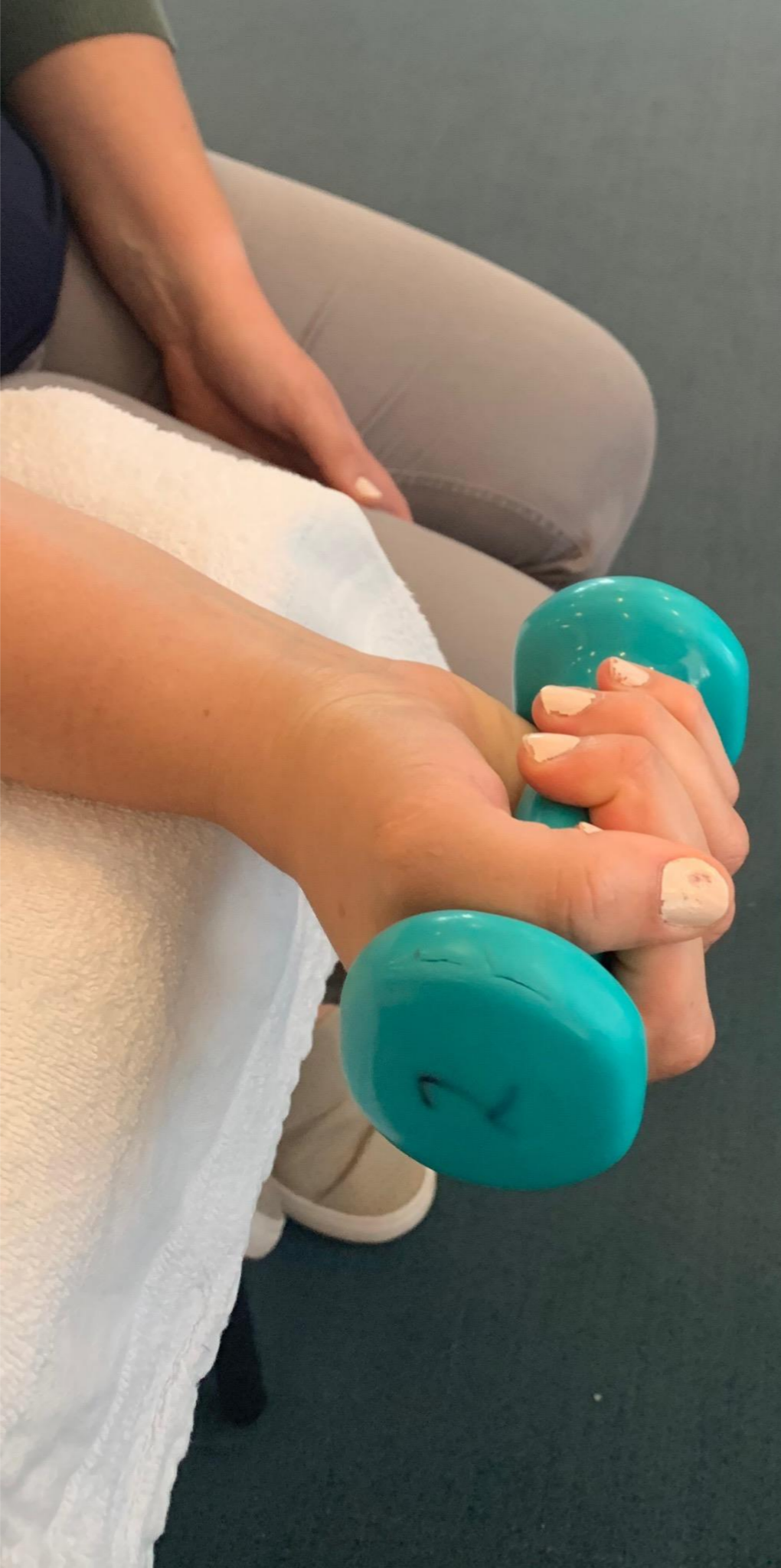

Management of fracture healing phase

- Realistic long term goals- focus on advancement of the HEP.
- Monitor progress with grip, pinch strength testing, ROM progression, function of wrist extensors and and tolerance for supination with light loads. “push off test” for weight bearing with complete fracture healing and if no ulnar sided wrist pain.
- Adjust applied forces for strengthening with respect outcomes of fracture stabilization pain level, if inflammation is present, and for patient demands for function.









Patient can be expected to improve for at least a year with regards to ROM and grip strength following DRF.

ROB et al JHS 2014